

Mycobacterium ulcerans (Buruli ulcer) disease

Fact sheet

Introductory statement

Mycobacterium ulcerans disease - referred to globally as Buruli ulcer (BU), also as 'Bairnsdale ulcer' in Victoria and 'Daintree ulcer' in Queensland - is recognised as one of the world's neglected tropical diseases. Infection in humans is characterised by progressive, painless destruction and necrosis of the skin, leading to the formation of ulcers. Australia is the only developed country with significant local transmission of *M. ulcerans* disease in humans and the only country to report the disease in wild animals. The mode of transmission and environmental reservoir are not completely understood, but research in Australia suggests a potential role for small mammals, particularly possums, in the ecology of this pathogen.

Aetiology

Mycobacterium ulcerans [MU] (Family *Mycobacteriaceae*) is a slow growing mycobacterium, closely related to *M. marinum*. The bacterium produces a destructive toxin, mycolactone, which causes tissue damage and inhibits the local immune response.

Natural hosts

The bacterium has been reported a range of both domestic and wildlife mammalian species in endemic areas of Australia. Laboratory-confirmed cases have been diagnosed in humans, koalas (*Phascolarctos cinereus*) (McOrist et al. 1985), common ringtail possums (*Pseudocheirus peregrinus*), a common brushtail possum (*Trichosurus vulpecula*), a mountain brushtail possum (*T. cunninghami*), a long-footed potoroo (*Potorous longipes*), a black rat (*Rattus rattus*)¹ as well as horses, dogs, a cat and an alpaca. The organism has been found in the faeces of ringtail and brushtail possums and northern brown bandicoots (*Isodon macrourus*) (Fyfe et al. 2010; Carson et al. 2014; O'Brien et al. 2014; Röltgen et al. 2017).

¹ National wildlife health information system (eWHIS) data.

World distribution

Human disease occurs in over 30 countries worldwide. Foci of infection have been reported in Australia (see below), Africa (e.g. Benin, Cote d'Ivoire and Ghana), Asia and the Western Pacific (e.g. Japan and Papua New Guinea), and the Americas (e.g. French Guiana). Australia is the only country to report the disease in animals other than humans.

Occurrences in Australia

There are at least three long-standing and recognised endemic areas for BU in humans in Australia: East Gippsland near Bairnsdale, Vic; Far North Qld (FNQ) between Mossman and the Daintree River, and the Capricorn Coast of Qld. Since the 1990s, new endemic areas have emerged on the Bellarine and Mornington Peninsulas of Vic, not far from Melbourne. Case numbers in humans have increased significantly in Vic, as have the number of human cases associated with severe disease (Tai et al. 2018).

Laboratory-confirmed cases of *M. ulcerans* disease in wildlife have only been reported in Vic. All reported cases in wildlife have been identified in locations where human cases have also occurred. There have been no confirmed cases of *M. ulcerans* disease in wildlife in Qld, NT or other states. In NSW, in reptiles, there have been confirmed infections with a different subspecies of *M. ulcerans*, not associated with human disease (J Fyfe pers. comm. September 2018).

Epidemiology

Globally, the geographic distribution of human BU case clusters is always highly focal (Carson et al. 2014).

The epidemiology of *M. ulcerans* disease in Australia is not well understood and appears to be changing in south-east Australia, with increasing numbers of human cases and expansion into new geographic areas (Tai et al. 2018). The reasons for the change in epidemiology are not known. Most recent Australian studies have focused on endemic and emerging-endemic areas in Victoria.

The incubation period is unknown in animals, but in humans it may be as long as several months (median 4.5 months) (Trubiano et al. 2013). Humans come into contact with the pathogen only in specific geographic areas, which are frequently near water bodies – either along coastal areas or inland near slow flowing rivers, swamps and lakes. The mode of transmission is unknown, but it is considered an environmental pathogen and there is no evidence to indicate that the disease is transmitted from person to person (or animal to animal, or animal to human). It is possible that there are different modes of transmission for different geographic and epidemiological scenarios (Singh et al. 2018) and that there are differences in virulence across geographically separate strains. Evidence suggests transmission may occur after exposure times of less than two hours (Trubiano et al. 2013). Because of the long incubation period in humans (and frequently an extended period to diagnosis), it may be difficult to accurately interpret the exposure history. These complications have hindered an understanding of the epidemiology.

Clinical cases have been reported in a range of marsupial species from endemic areas of Vic (Fyfe et al. 2010; O'Brien et al. 2014). There appears to be a significant disease burden in ringtail possums in some areas and adult animals appear to be most commonly affected. Ringtail possums appear more likely to have persistent lesions and to suffer from systemic disease associated with BU than other infected marsupials (O'Brien et al. 2014).

Research has investigated a potential role for a mammalian reservoir and/ or amplifying host. In Vic, common ringtail and common brushtail possums from endemic areas, both with and without clinical disease, have been shown to shed *M. ulcerans* in their faeces (Fyfe et al. 2010; Carson et al. 2014; O'Brien et al. 2014). Focal areas of high prevalence of MU in possum faeces, corresponded to focal areas of human cases (Fyfe et al. 2010; Carson et al. 2014). These findings could reflect a common environmental source of infection or may suggest an epidemiologically important role for possums. One hypothesis is that possums may act as a reservoir of *M. ulcerans* in SE Australia; they may ingest the organism from the environment, amplify it and shed it in the faeces.

The epidemiological model in FNQ appears to be different to SE Australia, with outbreaks occurring sporadically, possibly associated with heavy rainfall and associated environmental changes. Research in these areas found MU in northern brown bandicoot faeces, indicating a possible role for this wildlife species in the ecology of *M. ulcerans* disease (Röltgen et al. 2017).

Research also suggests a possible role for mosquitoes or other biting vectors in the transmission of *M. ulcerans* from the environment to humans (Johnson et al. 2007; Quek et al. 2007; Johnson and Lavender 2009; Wallace et al. 2017), however it is likely that there are several routes of infection, including possibly other puncturing injuries (Wallace et al. 2017).

Clinical signs

In wildlife, the most common clinical presentation is an ulcer or lesion, usually on the animal's nose, ear, paw or tail (Fig. 1). Behavioural signs may include lethargy, limited movement and, in the case of koalas, resting on the ground. Non-healing ulcers are typical also in humans and other domestic animals.

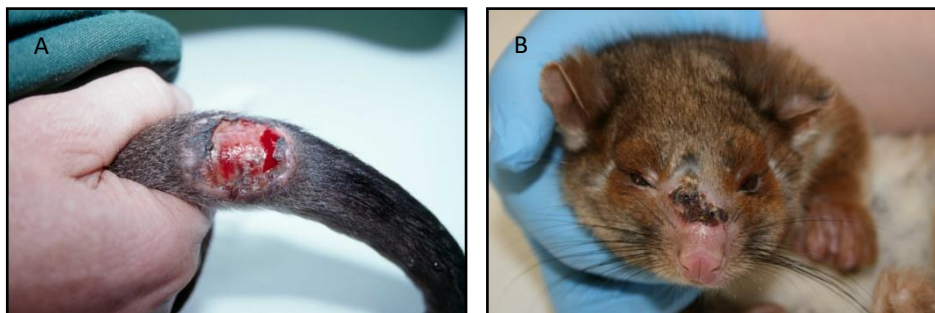


Figure 1. A. Long-footed potoroo with large lesion at the base of the tail. B. Ringtail possum with lesion on the nose.

Diagnosis

Animal lives in an endemic area.

Animal has an ulcer with no other apparent cause, usually on an extremity, and often with undermined edges. Acid-fast bacilli demonstrated in diagnostic specimens.

Clinical pathology

Undermined skin ulcer, with necrotic fat frequently visible at the base (Fig. 1).

There may be only minimal inflammatory response.

Pathology

Most cases of *M. ulcerans* in wildlife exhibit cutaneous ulcerative lesions, sub-cutaneous nodules or swelling of paws, limbs or digits. Systemic infection is also known to occur. Necropsy examinations of a long-footed potoroo, koalas and ringtail possums have revealed the presence of *M. ulcerans* in internal organs as well as lesions (Fig. 2).

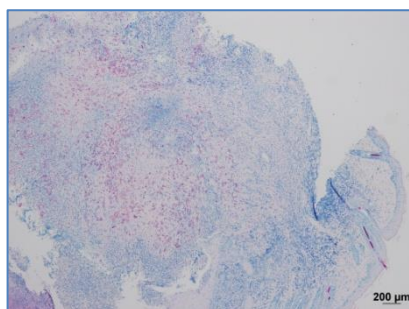


Figure 2. Ziehl-Neelsen (ZN)-stained section from nose lesion of ringtail possum.

Differential diagnoses

Traumatic skin ulcers, other mycobacterial and infectious skin ulcers.

Laboratory diagnostic specimens

- swabs (dry or in transport medium)
- fresh tissue
- paraffin-embedded fixed tissue sections.

Laboratory procedures

- direct smear examination for acid fast bacilli (AFB)
- culture for *M. ulcerans*
- polymerase chain reaction (PCR)
- histopathology.

PCR is the most rapid, sensitive and specific method for the diagnosis of *M. ulcerans* disease (Fyfe et al. 2007). This test is performed at the Victorian Infectious Diseases Reference Laboratory (address: 792 Elizabeth St, Melbourne 3000, phone: 03 9342 9379, <http://www.vidrl.org.au>). It is advisable to contact the laboratory prior to sending a specimen for testing.

Treatment

Various medical and surgical methods have been used to treat *M. ulcerans* disease in domestic animals, including antibiotic treatment, surgical excision and cryosurgery (Elsner et al. 2008; van Zyl et al. 2010; O'Brien et al. 2011). In wildlife, the infection has been known to resolve without treatment, as in the case of a mountain brushtail possum from Bellbird Creek (Fig. 3) and a brushtail possum from Point Lonsdale (unpublished). In severe cases, animals have been euthanased. Human treatment is not addressed in this fact sheet.



Figure 3. Mountain brushtail possum with lesion (A) at diagnosis and (B) later without treatment.

Prevention and control

While the mode of transmission of *M. ulcerans* is unknown, effective strategies for prevention and control of the disease remain to be devised. Referral of diseased animals for treatment or euthanasia by veterinarians experienced in the diagnosis of this condition is recommended.

Surveillance and management

There is no targeted surveillance program for *M. ulcerans* disease in wildlife. A greater awareness of the disease among veterinarians and wildlife carers, particularly in endemic areas such as Raymond Island, Phillip Island and the Bellarine and Mornington Peninsulas, as well as active case finding as part of research, has led to increased reporting of cases in wildlife and domestic animals.

Statistics

The WHO Collaborating Centre for *Mycobacterium ulcerans* - based at the Victorian Infectious Diseases Reference Laboratory (VIDRL) in Melbourne - maintains records of all known human and animal cases of *M. ulcerans* disease in Australia. In Victoria, the Department of Health publishes statistics on notifiable infectious diseases (in humans), including *M. ulcerans* infection, on its website <https://www2.health.vic.gov.au/>.

Wildlife disease surveillance in Australia is coordinated by Wildlife Health Australia. The National Wildlife Health Information System (eWHIS) captures information from a variety of sources including Australian government agencies, zoo and wildlife parks, wildlife carers, universities and members of the public. Coordinators in each of Australia's States and Territories report monthly on significant wildlife cases identified in their jurisdictions. NOTE: access to information contained within the National Wildlife Health Information System dataset is by application. Please contact admin@wildlifehealthaustralia.com.au. There are almost 30 cases reported in eWHIS from free-living marsupials from endemic areas of Victoria, mostly in ringtail possums.

A study found 9/42 ringtail and 1/21 brushtail possums examined at an endemic Victorian site had clinical BU lesions. Of these cases, 82% (9/11) of ringtail possums also had MU positive faeces, compared to 16% (5/31) of ringtail possums without BU lesions, at the same location (Fyfe et al. 2010).

Research

The WHO has identified six main priorities for research into BU: mode of transmission; development of simple diagnostic tests; drug treatments and new treatment modalities; development of vaccines; social and economic studies; and studies to determine the incidence and prevalence.

In Australia, much research has focussed on determining the mode of transmission and environmental source of *M. ulcerans*. Further work is needed to gain a better understanding of the potential role of ringtail and/or brushtail possums, if there are any epidemiological interactions between these two species, and whether the relative population density of ringtail and brushtail possums influences endemicity and/or emergence of BU in humans. Possum faecal surveys may provide a useful public health monitoring tool and may act as sentinels for incidence in humans.

Work is required to better understand the prevalence of MU lesions in possums in human endemic areas, the susceptibility of different Australian marsupial species to MU infection, the possibility of gut amplification in marsupial species and whether *M. ulcerans* disease poses a risk to populations of possums or other marsupial species.

Genomic studies could help to explore whether different pathogen strains are associated with different virulence, and whether strains are evolving and changing in virulence over time (Tai et al. 2018).

Human health implications

Mycobacterium ulcerans infection is primarily a human disease and is notifiable in the state of Victoria. The source of infection in humans remains unknown and there are no confirmed cases of transmission from wildlife to humans. All age groups of humans are at risk, however severe disease is more common in older patients (Tai et al. 2018).

Conclusions

There is much to be learned about *M. ulcerans* disease. Further research is needed to better understand the possible epidemiological role of possums or other marsupials. The current wave of interest in important but less well known tropical diseases and the 'One Health' approach to health care for humans and animals will hopefully contribute to better visibility of the disease and help attract the resources needed to develop new tools for diagnosis, treatment, prevention and control.

References

- Carson C, Lavender CJ, Handasyde KA, O'Brien CR, Hewitt N, Johnson PD, Fyfe JA (2014) Potential wildlife sentinels for monitoring the endemic spread of human buruli ulcer in South-East Australia. *PLOS Neglected Tropical Diseases* **8**, e2668.
- Elsner L, Wayne J, O'Brien CR, McCowan C, Malik R, Hayman JA, Globan M, Lavender CJ, Fyfe JA (2008) Localised *Mycobacterium ulcerans* infection in a cat in Australia. *Journal of Feline Medicine & Surgery* **10**, 407-12.
- Fyfe JA, Lavender CJ, Handasyde KA, Legione AR, O'Brien CR, Stinear TP, Pidot SJ, Seemann T, Benbow ME, Wallace JR, McCowan C, Johnson PD (2010) A Major Role for Mammals in the Ecology of *Mycobacterium ulcerans*. *PLOS Neglected Tropical Diseases* **4**, e791.

Fyfe JA, Lavender CJ, Johnson PD, Globan M, Sievers A, Aзуolas J, Stinear TP (2007) Development and application of two multiplex real-time PCR assays for the detection of *Mycobacterium ulcerans* in clinical and environmental samples. *Applied and Environmental Microbiology* **73**, 4733-4740.

Johnson P, Aзуolas J, Lavender CJ, Wishart E, Stinear TP, Hayman JA, Brown L, Jenkin GA, Fyfe JAM (2007) *Mycobacterium ulcerans* in mosquitoes captured during an outbreak of Buruli ulcer, southeastern Australia. *Emerging Infectious Diseases* **13**, 1653-1660.

Johnson P, Lavender C (2009) Correlation between Buruli ulcer and vector-borne notifiable diseases, Victoria, Australia. *Emerging Infectious Diseases* **15**, 614-615.

McOrist S, Jerrett IV, Anderson M, Hayman J (1985) Cutaneous and respiratory tract infection with *Mycobacterium ulcerans* in two koalas (*Phascolarctos cinereus*). *Journal of Wildlife Diseases* **21**, 171-173.

O'Brien C, Handasyde KA, Hibble J, Lavender CJ, Legione AR, McCowan C, Globan M, Mitchell AT, McCracken HE, Johnson PD (2014) Clinical, microbiological and pathological findings of *Mycobacterium ulcerans* infection in three Australian Possum species. *PLOS Neglected Tropical Diseases* **8**, e2666.

O'Brien C, McMillan E, Harris O, O'Brien DP, Lavender CJ, Globan M, Legione AR, Fyfe JA (2011) Localised *Mycobacterium ulcerans* infection in four dogs. *Australian Veterinary Journal* **89**, 506-10.

Quek TY, Athan E, Henry MJ, Pasco JA, Redden-Hoare J, Hughes A, Johnson PD (2007) Risk factors for *Mycobacterium ulcerans* infection, southeastern Australia. *Emerging Infectious Diseases* **13**, 1661-6.

Röltgen K, Pluschke G, Johnson PD, Fyfe J (2017) *Mycobacterium ulcerans* DNA in Bandicoot Excreta in Buruli Ulcer–Endemic Area, Northern Queensland, Australia. *Emerging Infectious Diseases* **23**, 2042.

Singh A, McBride W, Govan B, Pearson M (2018) Potential Animal Reservoir of *Mycobacterium ulcerans*: A Systematic Review. *Tropical Medicine and Infectious Disease* **3**, 56.

Tai AY, Athan E, Friedman ND, Hughes A, Walton A, O'Brien DP (2018) Increased Severity and Spread of *Mycobacterium ulcerans*, Southeastern Australia. *Emerging Infectious Diseases* **24**, 58.

Trubiano JA, Lavender CJ, Fyfe JA, Bittmann S, Johnson PD (2013) The incubation period of Buruli ulcer (*Mycobacterium ulcerans* infection). *PLOS Neglected Tropical Diseases* **7**, e2463.

van Zyl A, Daniel J, Wayne J, McCowan C, Malik R, Jelfs P, Lavender C, Fyfe J (2010) *Mycobacterium ulcerans* infections in two horses in south-eastern Australia. *Australia Veterinary Journal* **88**, 101-106.

Wallace JR, Mangas KM, Porter JL, Marcisisin R, Pidot SJ, Howden B, Omansen TF, Zeng W, Axford JK, Johnson PDR, Stinear TP (2017) *Mycobacterium ulcerans* low infectious dose and mechanical transmission support insect bites and puncturing injuries in the spread of Buruli ulcer. *PLOS Neglected Tropical Diseases* **11**, e0005553.

Acknowledgements

We are extremely grateful to the many people who had input into this fact sheet and would specifically like to thank the Victorian Infectious Diseases Reference Laboratory (VIDRL), Christina McCowan, Caroline Lavender, Janet Fyfe and John Hayman who have a special interest in this condition in Australia.

Updated: September 2018

To provide feedback on this fact sheet

We are interested in hearing from anyone with information on this condition in Australia, including laboratory reports, historical datasets or survey results that could be added to the National Wildlife Health Information System. If you can help, please contact us at admin@wildlifehealthaustralia.com.au.

Wildlife Health Australia would be very grateful for any feedback on this fact sheet. Please provide detailed comments or suggestions to admin@wildlifehealthaustralia.com.au. We would also like to hear from you if you have a particular area of expertise and would like to produce a fact sheet (or sheets) for the network (or update current sheets). A small amount of funding is available to facilitate this.

Disclaimer

This fact sheet is managed by Wildlife Health Australia for information purposes only. Information contained in it is drawn from a variety of sources external to Wildlife Health Australia. Although reasonable care was taken in its preparation, Wildlife Health Australia does not guarantee or warrant the accuracy, reliability, completeness, or currency of the information or its usefulness in achieving any purpose. It should not be relied on in place of professional veterinary consultation. To the fullest extent permitted by law, Wildlife Health Australia will not be liable for any loss, damage, cost or expense incurred in or arising by reason of any person relying on information in this fact sheet. Persons should accordingly make and rely on their own assessments and enquiries to verify the accuracy of the information provided.



Find out more at www.wildlifehealthaustralia.com.au
email admin@wildlifehealthaustralia.com.au
or call +61 2 9960 6333